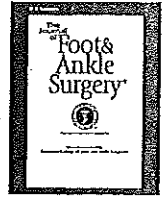




Contents lists available at ScienceDirect

The Journal of Foot & Ankle Surgery

journal homepage: www.jfas.org



Inverted Z-scarf Osteotomy for Hallux Valgus Deformity Correction: Intermediate-term Results in 55 Patients

J. Michael Miller, DPM¹, Vafa N. Ferdowsian, DPM², David R. Collman, DPM³

¹ Director, Fellowship in Reconstructive Foot & Ankle Surgery, American Health Network of Indiana, LLC; Private practice, Avon and Carmel, IN

² Private practice, Conway, AR

³ Department of Orthopedics/Podiatry, Kaiser Foundation Hospital, Modesto/Manteca, CA

ARTICLE INFO

Level of Clinical Evidence: 2

Keywords:

bunionectomy

foot

metatarsal

surgery

toe

ABSTRACT

The Z-scarf osteotomy is used for hallux valgus deformity correction by foot and ankle surgeons worldwide. Inverting the Z-scarf osteotomy configuration strengthens the construct in both sawbone and cadaver models, but clinical results of this configuration have not been reported in the literature. This retrospective study evaluates the subjective and intermediate-term postoperative radiographic results of 73 inverted Z-scarf osteotomy procedures for hallux valgus correction in 55 patients from January 1994 to December 2003. The modified University of Maryland 100-Point Painful Foot Center Scoring System demonstrated 52 patients (95%) with good to excellent results at a mean follow-up of 5 years (range 2–11 years). Radiograph measurements revealed the following: first-second intermetatarsal angle mean, 6.1° (range 2–14°), average reduction 4.6°; hallux abductus angle mean, 11.0° (range –8–30°), average reduction 10.1°; tibial sesamoid position mean, 2.3; first metatarsal protrusion distance mean, –2.1 mm. Two patients (2 of 73 feet) developed major complications: one progressed to clinically acceptable hallux varus; another sustained compromise of one fixation screw with minor displacement at the distal osteotomy that healed in satisfactory position after non-weight-bearing immobilization. There were no cases of osteonecrosis, delayed union, or nonunion. The inverted Z-scarf osteotomy, with advantages in both mechanical strength and technique of execution over the traditional configuration, demonstrates high patient satisfaction, restoration of normal radiographic parameters, and a low complication rate in this study.

© 2011 by the American College of Foot and Ankle Surgeons. All rights reserved.

Numerous surgical approaches for the correction of hallux valgus deformity have been devised, with at least 130 different procedures described to date (1). *Scarf* is a carpentry term that represents an interlocking Z cut. Meyer (2) first described the Z-scarf osteotomy for hallux valgus correction with the Z cut oriented in the sagittal plane. In 1983, C.J. Gudas, DPM and K.H. Zygmunt, DPM (oral communication, January 1992) modified the Z osteotomy for correction of metatarsus primus varus with bunion deformity by orienting it in the transverse plane: 2 shorter arms—distal dorsal exit and proximal plantar exit—are angled 60 to 80° to the longitudinal central osteotomy. This configuration was further modified, moving the longitudinal osteotomy to the plantar one-third of the metatarsal shaft to reduce fracture risk via a smaller proximal arm, and widely used at the University of Chicago in 1100 reported cases (3). Weil (4, 5) and

Barouk (6, 7) contributed to the global recognition and development of the transverse Z-scarf osteotomy. Its inherent stability and versatility have made the osteotomy popular among foot and ankle surgeons worldwide, particularly in Europe.

The traditional Z-scarf osteotomy has undergone a number of modifications since its introduction (3, 4, 8–15). Perhaps its most substantial revision was the introduction of the inverted Z-scarf osteotomy design in 1992 by Chang et al (12), who reversed the configuration of the proximal and distal arms. A consistent failure pattern was demonstrated near the proximal arm of the traditional Z-scarf osteotomy, requiring significantly less force to failure compared with the inverted construct in a sawbone model (12). Their findings were corroborated by Miller et al (13) in both sawbone models and matched pair cadaver specimens, demonstrating the inverted Z-scarf osteotomy to be 1.6 times inherently more stable to simulated weight-bearing forces compared with the traditional construct.

A number of studies have evaluated clinical and radiographic results of the traditional Z-scarf osteotomy and some of its modifications (3, 4, 9, 15–31); however, clinical results of the inverted construct have not been reported in the literature. The purpose of this

Financial Disclosure: None reported.

Conflicts of Interest: None reported.

Address correspondence to: David R. Collman, DPM, Department of Orthopedics/Podiatry, Kaiser Foundation Hospital, 4601 Dale Road, 1st Floor, Modesto, CA 95356.

E-mail address: drcollman@yahoo.com (D.R. Collman).

retrospective descriptive study was to evaluate clinical outcomes of the inverted Z-scarf osteotomy based on patient satisfaction scores and radiograph analysis. The authors were particularly interested in complications resulting from the osteotomy construct and patient perception of the outcome.

Patients and Methods

At the time of this investigation, there was no Institutional Review Board at the authors' medical group. Sixty-one nonconsecutive patients underwent 81 inverted Z-scarf osteotomies for the correction of hallux valgus deformity from January 1994 to December 2003 by the senior author (J.M.M.). Forty-one patients underwent surgery on one foot, whereas 20 patients had bilateral surgery (performed on different dates). No patients had previous surgery or underwent concomitant first metatarsal surgery during the index procedure. No patients had been diagnosed with diabetes mellitus, rheumatoid arthritis, peripheral vascular disease, or other systemic conditions. All patients failed conservative treatment that included at least a 6-month trial of shoe modifications, strapping or padding, and/or orthotics. Indications for surgery included a painful bunion deformity, first-second intermetatarsal angle of 15° or larger, absence of first metatarsal-cuneiform joint instability or hypermobility, minimal to no first metatarsophalangeal joint disease (defined as pain-free motion and minimal to no structural adaptation), and sufficient metatarsal width (defined as 20 mm or larger based on transverse linear intercondylar measurement of the first metatarsal head). Additional indications included adequate bone density as visually assessed on preoperative radiographs and a patient's desire to be weight bearing as soon as possible after the operation. Contraindications included osteopenic bone, a first-second intermetatarsal angle less than 15° , and a metatarsal width less than 20 mm based on the aforementioned measurement technique.

The operative technique has been described by Chang et al (12, 32) and modified by Miller et al (13). The original inverted Z-scarf construct involved a longitudinal osteotomy through the mid-portion of the first metatarsal shaft, followed by a connecting distal plantar osteotomy arm angled 60 to 80° in the metatarsal head (similar to the plantar arm of a chevron osteotomy) and proximal dorsal osteotomy also angled approximately 60 to 80° to the longitudinal shaft osteotomy. The modification by the senior author (J.M.M.) increases the angle of the proximal dorsal osteotomy to 120° (Figure 1). This alteration does not compromise the stability of the construct, reduces proximal segment binding that may occur during rotation of the capital fragment, and provides more dorsal surface area for screw placement (13).

In this series, the deformity was approached with a dorsal linear skin incision and capsulotomy. A lateral soft tissue release of the first metatarsophalangeal joint was performed and the medial eminence was removed. The inverted Z osteotomy was performed as described above. The dorsal metatarsal fragment was laterally translocated to the desired position for optimal reduction of the intermetatarsal angle and its distal aspect rotated medially to improve alignment of the metatarsal head cartilage if its malorientation was significant. The correction was maintained with a bone tenaculum and two 0.062-inch Kirschner wires placed perpendicular to the horizontal osteotomy. The proximal wire was placed first to allow the capital fragment to pivot for further rotational correction as desired. Each wire was then sequentially replaced with a 3.5-mm screw in standard Arbeitsgemeinschaft fuer Osteosynthesefragen-Association for the Study of Internal Fixation (AO/ASIF) technique, taking care not to compromise either point of fixation. Care was taken to ensure the hallux proximal phalanx was aligned on the first metatarsal head. If residual abductus of the hallux was noted following these steps, a hallux proximal phalanx closing basal wedge osteotomy was performed to attain the desired alignment and fixed with a wire-loop through

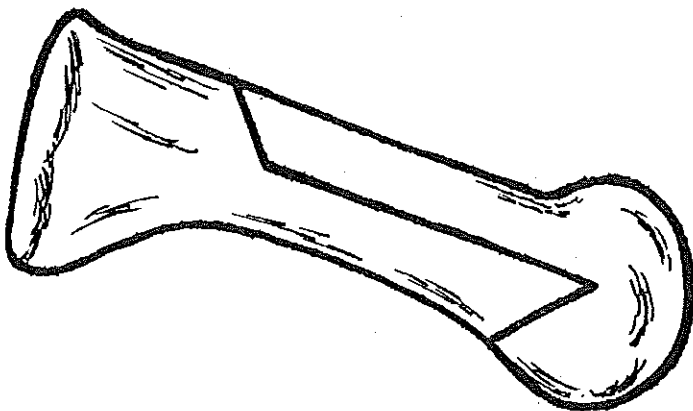


Fig. 1. The inverted Z osteotomy performed in this series, a modification of the traditional Z-scarf osteotomy.

adjacent drill holes. A medial capsulorrhaphy concluded the procedure and the soft tissue was closed in layers.

The postoperative protocol included weight bearing as tolerated in a surgical shoe with a first ray cut-out for the first 6 weeks and transition to weight bearing in tennis shoes during weeks 7 to 11. Full return to activity was permitted by week 10 to 12, after which time no further follow-up was required. If serial radiographs or clinical examination indicated signs not consistent with normal bone healing, return to full weight bearing was slowed on a case-by-case basis. Each patient was instructed on self-administered active first metatarsophalangeal joint range-of-motion exercises, which were instigated on postoperative week 1 and continued until week 12.

Outcome analysis was based on patient questionnaire, radiographic measurements, and medical chart review. Subjective results were evaluated via a mailed survey on average 5 years after surgery (range 2–11 years) by one author who was not involved in patient care (V.N.F.). Patient satisfaction was measured by the University of Maryland 100-Point Painful Foot Center Scoring System (33) as modified by Schoen et al (17) (Table 1). The system was not changed with respect to scoring categories, patient answer selection, or point allocation. However, it was adapted to focus on results specific to hallux valgus correction while obviating effects of concomitant limb or pedal symptoms (17). A score of 90 to 100 correlates with an excellent result, 75 to 90 a good result, 60 to 75 a fair result, and less than 60 a poor result. Table 1 depicts the modified scoring system that was sent to each patient and its questions pertaining to various categories of pain, function, and cosmesis. Because the operative foot was not specified in the questionnaire, answers were presumed to represent combined results for those patients who underwent bilateral procedures.

Radiographs were evaluated with measurements from standard anteroposterior and lateral foot views in relaxed angle and base of stance. All measurements were manually performed once and recorded from hard film images by one author (V.N.F.) on radiographs obtained on average 14 weeks after surgery (range 12–16 weeks). Measurements included first-second intermetatarsal angle, hallux abductus angle, tibial sesamoid position, and metatarsal protrusion distance (length of first metatarsal in reference to second metatarsal, with shorter comparative length reported as negative number) according to standard technique. All radiographs were taken by 2 nurses in the senior author's (J.M.M.) practice with standard procedures for radiographic film development.

One author (V.N.F.) reviewed medical records and correlated them with radiographs to determine postoperative complications. Major complications were defined as follows: first metatarsal fracture (intra- or postoperative); the development of hallux varus deformity (defined by the hallux proximal phalanx longitudinal bisection adducting past that of the first metatarsal); loss of deformity correction (defined by a postoperative radiographic increase of 5° for the hallux abductus angle or 3° for the first-second intermetatarsal angle); first ray elevation or depression compared with preoperative films (defined as greater than a 2 mm difference between the dorsal cortices of the first and second metatarsal mid-shaft on the lateral weight-bearing radiograph); osteonecrosis; delayed union, malunion, or nonunion; deep infection; and persistent neuralgia or the development of complex regional pain syndrome. Minor complications were defined as superficial infection and minor wound dehiscence. Patient variables such as age, body mass index, tobacco use, and activity level were not evaluated.

Results

The study population was composed of 55 women and 6 men. Fifty-five of 61 patients replied to the questionnaire, a response rate of 90%. Patient satisfaction was rated good to excellent by 52 patients (95%), with 3 patients reporting a fair result according to the modified University of Maryland 100-Point Painful Foot Center Scoring System (17, 33) (Table 2). Patient responses to the questionnaire demonstrated 53 patients (96%) with no pain or slight pain, whereas the remainder had mild or marked pain (1 patient each). Walking ability was unlimited or slightly diminished in 52 patients (94%). Fifty patients (90%) could walk on any surface and 52 patients (94%) could ascend stairs normally. Fifty-four patients (98%) required no support to walk, and 53 patients (96%) did not feel they had a limp. Only 26 patients (47%) could wear any type of shoe, whereas 20 patients reported they were unable to wear certain types of shoes or required flat heel shoes, and 9 patients felt they needed to wear orthotics in their shoes. Fifty patients (90%) felt their feet looked normal or had a mild deformity, whereas only 36 patients (65%) felt they had normal motion.

Follow-up radiographs were not available for 8 feet. Results from quantitative analysis of the remaining 73 radiographs are depicted in Table 3. The mean first-second intermetatarsal angle reduction was 4.6° . The mean reduction in the hallux abductus angle mean was 10.1° .

Table 1
Patient satisfaction as measured by the University of Maryland 100-Point Painful Foot Center Scoring System

	Points*
1. Regarding my bunion surgery, I presently have:	
A) No pain, including sports	45
B) Slight pain, but it does not affect my ability to work	40
C) Mild pain, but I have made only minimal changes in my daily activity	30
D) Moderate pain for which I take aspirin, Tylenol, Advil or other anti-inflammatory medication	20
E) Marked pain, even with minimal activities	10
F) Disabling pain for which I take stronger pain pills	0
2. With regard to the area of my bunion surgery and walking, my ability is:	
A) Unlimited	10
B) Slightly diminished	8
C) Moderately diminished	5
D) Severely diminished	2
E) Restricted to indoors only	0
3. With regard to how my bunion surgery influences my walking:	
A) I feel completely stable when I walk	4
B) I have a weak feeling when I walk	3
C) I have an occasional feeling of giving way	2
D) I have instability when I walk (frequent feeling of giving way)	1
E) I need support or assistance to walk	0
4. With regard to my area of bunion surgery and support for walking:	
A) I do not require any support to walk	4
B) I require a cane to walk because of my foot	3
C) I require crutches to walk	1
D) I require a wheelchair	0
5. With regard to my bunion surgery and walking:	
A) I do not feel that I have a limp	4
B) I have a slight limp	3
C) I have a moderate limp	2
D) I have a severe limp	1
E) I cannot walk	0
6. With regard to the area of my bunion surgery and footwear:	
A) I can comfortably wear any type of shoe	10
B) There are some shoes I cannot wear	9
C) I can wear only flat heel shoes	7
D) I need to wear orthotics or supportive inserts in my shoes	5
E) I wear special extra depth or "orthopedic shoes"	2
7. With regard to the area of my bunion surgery and walking:	
A) I can walk on any surface or terrain	4
B) I have problems walking up and down hills	2
C) I have problems walking on flat surfaces	0
8. With regard to my bunion surgery and walking:	
A) I can go up stairs normally	4
B) I need to use the banister	3
C) I need assistance going up and down stairs	2
D) I am unable to go up and down stairs	0
9. With regard to the area of my bunion surgery and the appearance of my foot:	
A) I feel my foot looks normal	10
B) It looks like I have a mild deformity	7
C) It looks like I have a moderate deformity	5
D) It looks like I have a severe deformity	0
10. With regard to my bunion surgery and the motion I now have in my big toe joint(s):	
A) I feel I have normal motion	5
B) I feel my motion is slightly decreased	4
C) I feel my motion is markedly decreased	0
Total	100

* Point distribution for answer responses are not part of the questionnaire given to the patient. Adapted from (33) as modified by Schoen et al (17).

One radiograph demonstrated approximately 2 mm of distal first metatarsal elevation, whereas plantarflexion deformity was not observed on any radiograph. In those patients where it was performed, there were no fractures or healing complications at the hallux proximal phalanx closing basal wedge osteotomy. Figure 2 demonstrates the typical hallux valgus deformity correction attained with the inverted Z-scarf osteotomy in this series.

Two patients developed major complications, a rate of 2.7% (2 of 73 feet). In one patient, serial radiographs demonstrated mild distal screw pull-out from the plantar cortex of the distal metatarsal shaft, which resulted in 2 mm of dorsal displacement of the capital fragment. The osteotomy healed in mild malunion after non-weight-bearing immobilization, although alignment was satisfactory and

there was no loss of deformity correction. One patient developed a latent hallux varus identified by approximately 8° of adduction on the radiograph. However, clinical alignment was acceptable and the patient did not desire revision surgery.

Postoperative radiograph measurements demonstrated no recurrence of hallux valgus or metatarsus primus varus deformity on average 14 weeks after surgery (range 12–16 weeks). There were no cases of osteonecrosis, nor was there any case of delayed union or nonunion of the first metatarsal. There were no deep infections and no cases of persistent neuralgia or the development of complex regional pain syndrome. Three patients sustained minor complications: 2 patients developed mild local cellulitis around the incision site that resolved after 1 week of oral antibiotics, and 1 patient

Table 2
Patient satisfaction as rated by patients

Score	Rating	Patients (N)	Patients (%)
90-100	EXCELLENT	46	84
75-90	GOOD	6	11
60-75	FAIR	3	5
<60	POOR	0	0

Modified University of Maryland 100-Point Painful Foot Center Scoring System (17,33).

developed mild wound dehiscence that resolved after local wound care.

Discussion

The Z-scarf osteotomy is a versatile mid-shaft procedure for the correction of hallux valgus deformity that has gained considerable popularity, particularly in Europe. Since its introduction in 1983, the applications of this osteotomy have expanded to include not only first intermetatarsal angle reduction of various magnitudes and derotation of the capital fragment for cartilage deviation, but also sagittal plane displacement of the capital fragment to increase or diminish first ray load as well as elongation or shortening for a short or long metatarsal, respectively (4, 6). A number of modifications for the traditional configuration of the Z-scarf osteotomy have been described in the literature, all of which retain the commonality of the general

Table 3
Results from quantitative analysis of the 73 radiographs

Measurement	Mean	Range
Intermetatarsal angle	6.1°	2-14°
Hallux abductus angle	11.0°	-8-30°
Tibial sesamoid position	2.3	1-7
Metatarsal protrusion	-2.1 mm	-5-6 mm

Follow-up radiographs were not available for 8 feet.

orientation of the original Z osteotomy with internal fixation accompanied by a lateral soft tissue release, removal of the bunion, and a medial capsulorrhaphy (3, 4, 8–11, 14, 15).

Much of the clinical research on the traditional Z-scarf osteotomy for hallux valgus correction reports short-term outcomes (3, 8, 9, 15, 16, 18, 20–22, 24, 34); however, a number of more recent studies have evaluated intermediate-term results (23, 25–27, 29–31). Thirteen studies have assessed outcomes based on subjective patient survey, objective clinical review, and radiographic measurements, reporting primarily good to excellent results in populations ranging from 20 to 89 patients (20–111 feet, respectively) (3, 17, 18, 20, 21, 24–27, 29–31).

Comparing the current investigation with previous studies of similar numbers of patients or mean follow-up undergoing Scarf osteotomy for hallux valgus correction reveals similar positive outcomes. Good to excellent results have been reported for 70% to 90%

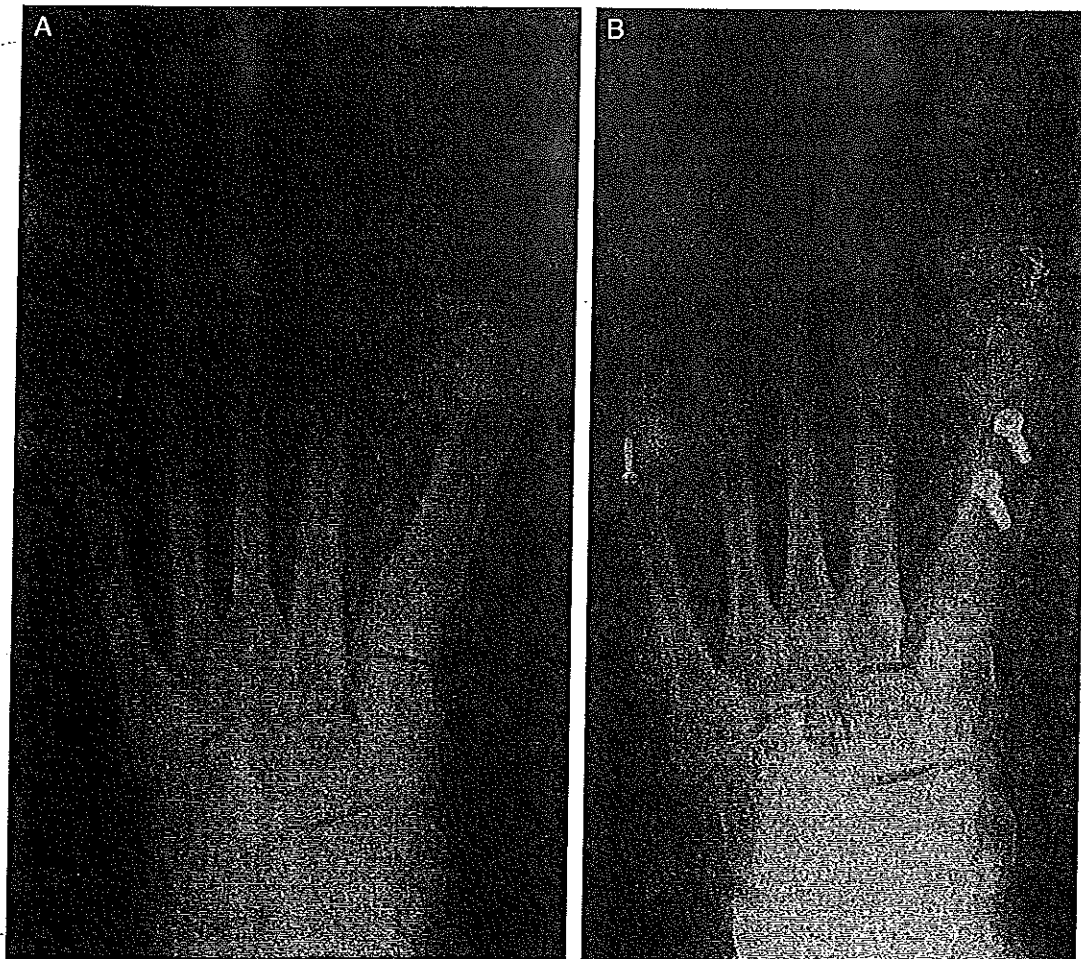


Fig. 2. AP weight-bearing radiographs depict correction of hallux valgus deformity attained with the inverted Z-scarf osteotomy construct in this series. (A) Preoperative radiograph. (B) Postoperative radiograph. Note the rotated position of the capital fragment/superior arm to maintain cortical apposition of the metatarsal.

of patients in previous studies based on questionnaires, radiographs, and clinical evaluation (17, 23, 25, 29). Several recent pedobarographic studies have shown either no detrimental results or improved functional outcome after the scarf osteotomy (24, 26, 35). Interestingly, one prospective study of 32 patients at a mean follow-up of 33 months found the scarf osteotomy increased forces under the first metatarsal head, improving the contribution of the first ray and helping to restore forefoot function in gait (26). Similar results of increased pressure under the first metatarsal head and significant improvement in clinical function 6 months after the scarf osteotomy have been reported (35).

To our knowledge, this study is the first to evaluate outcomes of the inverted Z-scarf osteotomy for hallux valgus correction. The patient survey was a major component for outcome analysis and demonstrated primarily good to excellent results: 95% overall satisfaction, 96% of patients with no or slight pain, 90% to 98% of patients with favorable walking ability, and 90% of patients perceiving their foot appearance to be acceptable. The less favorable patient survey results were reported in the categories of shoe gear and motion. The comfortable use of unrestricted shoe gear was limited to 47% of patients in this study. This result is surprising given that many patients likely seek bunion deformity correction because of pain in shoes they desire to wear. Shoe gear limitations could result from a number of factors related to both surgery and patient characteristics. An uncomfortable or unsightly scar, reduced first metatarsophalangeal joint motion, or unrealistic patient expectations about a panacea correction for their foot problem could all contribute to patient perceptions about shoe comfort and wear characteristics. The index procedure may have simply failed to address underlying structural deformities of the foot that preclude wearing certain types of shoes. Moreover, the survey may have posed inherent limitations in assessing this outcome, given that patient responses to overall satisfaction, pain, walking ability, and foot appearance were 90% or higher. Only 65% of patients believed they had normal motion of the first metatarsophalangeal joint, which may have contributed to shoe gear restrictions. This result could be explained by scar tissue and failure to perform adequate range-of-motion exercises. However, this result did not appear to adversely affect the overall high satisfaction scores for the procedure.

Radiographic measurements in this study demonstrated standard postoperative parameters for hallux valgus correction (Table 2) to be comparable to a similar study of the traditional configuration of the Z-scarf osteotomy, with the exception of a higher mean hallux abductus angle in our study (17). However, despite a 20% incidence of radiographic hallux varus in the study by Schoen et al (17), 94% of patients considered their foot to appear normal or have mild deformity. Yet most cases of hallux varus or adductus in that series were mild and the authors suggest that patients desired a rectus hallux after surgery, the survey results supporting acceptance of this position (17). The radiographic incidence of hallux varus was considerably lower in our series, with only one patient developing a deformity by radiographic measurements that was deemed clinically acceptable and left the patient satisfied with the toe position. Patient questionnaire results demonstrated 90% satisfaction with foot appearance, suggesting that both a position of mild hallux abductus and a more rectus attitude are deemed acceptable for hallux valgus correction in this series. However, with the exception of the aforementioned case of hallux varus, no correlation was made between individual patient surveys and their respective radiographs, precluding a case-by-case determination of patient satisfaction about toe position.

The results of short- and intermediate-term outcome studies on the traditional Z-scarf osteotomy and its various modifications for hallux valgus correction demonstrate that the major overall complication rate averages 8% (range 0%–35%) (3, 8, 9, 15, 17, 18, 21, 22, 24–31,

36). Such complications include metatarsal fracture (acute or latent), troughing (the medial metatarsal cortex opposes the medullary canal upon lateral translation of the plantar fragment), hallux varus, osteonecrosis, delayed union or malunion, deformity recurrence, persistent neuralgia, complex regional pain syndrome, and deep vein thrombosis. Major complications were limited to several cases in 6 studies (3, 20, 21, 24, 28, 30). However, 1 study of 71 patients (84 feet) reported that 11% of patients required a revision operation within 22 months and attributed this result to different surgeons at a teaching hospital (18). Moreover, Coetzee (22) cautioned against the widespread use of the Z-scarf osteotomy, citing numerous complications, 25% early deformity recurrence, and a nearly 50% patient dissatisfaction rate in his study of 20 patients at 6- and 12-month follow-up. Two of the more catastrophic complications that have been reported in the literature include troughing along the first metatarsal with the subsequent development of first metatarsal elevation (and potential for lesser metatarsal head overload), and acute or latent fracture of the first metatarsal (3, 10–13, 15, 17, 18, 22, 24, 25, 32, 36).

The incidence of first metatarsal troughing and subsequent metatarsal elevation and valgus deviation in the traditional Z-scarf osteotomy is difficult to determine from the available literature. Although this complication has been widely recognized as an inherent risk with the osteotomy, only a few studies have documented this complication (10, 11, 22). Steck and Ringstrom (11) suggested an annual incidence of less than 2% per 60 cases. Other authors have noted postoperative elevation of the first metatarsal in their series, but this was not clearly linked to a positional shift of the plantar or distal fragment of the osteotomy (17, 18). Although Schoen et al (17) suggested that their patients may have had preexisting asymptomatic first metatarsal elevation, they acknowledged the risk of troughing in osteopenic bone, advised limited passes of the saw, and cautioned against pushing the limits of lateral translocation. Finally, most studies have not compared the pre- versus postoperative incidence of pain or skin callus beneath the lesser metatarsals as it relates to the position of the first metatarsal.

Troughing was not an observed complication in this study. This problem was most likely avoided by transverse rotation of the capital fragment on the plantar metatarsal segment to maximize cortical apposition, a technique that also served to realign the cartilage at the first metatarsal head. Excessive lateral translocation was avoided, which also helped prevent the problem, as suggested by other authors (17). In theory, first metatarsal troughing in the inverted Z-scarf osteotomy construct would result in plantarflexion of the dorsal fragment on the plantar shelf of the metatarsal (12, 13). Indeed, one of the advantages of the inverted Z-scarf osteotomy is that its design precludes the possibility of first metatarsal elevation with sound fixation in healthy bone. Should metatarsal troughing occur with this construct, the risk of lesser metatarsal overload resulting from first metatarsal elevation is theoretically minimal. However, plantar troughing risks sesamoid overload, also a difficult problem to manage. First metatarsal plantarflexion was not observed on any of the 73 follow-up radiographs in this series. Aside from careful patient selection, attention to detail with operative technique—especially maintaining 2 points of fixation at all times—is central to minimizing the risk of troughing in either the more traditional or the inverted Z-scarf osteotomy.

It is likely that first metatarsal fractures are responsible for more cases of first metatarsal elevation than metatarsal troughing in the traditional Z-scarf osteotomy. The overall incidence of first metatarsal fractures in this osteotomy construct and its various modifications is 3% (range 0%–10%) based on reports the literature (3, 7–9, 15, 17, 18, 21, 22, 24, 25, 36). A postoperative fracture pattern propagating dorsally from the mechanically weak proximal plantar arm of the osteotomy has been observed by a number of authors (3, 15, 22, 32). The proximal plantar osteotomy in the traditional Z-scarf design has been shown to

produce a stress riser across the intact dorsal shelf, producing dorsal migration of the first metatarsal via a consistent fracture pattern at this site in both sawbone models and matched cadaver specimens (Figure 3) (12, 13). In addition to C.J. Gudas, DPM's (oral communication, January 1992) original modification to the osteotomy, other surgeons have revised the construct to increase the surface area across the dorsal shelf by moving the longitudinal arm from the first metatarsal bisection to the plantar one-third of the bone, thereby reducing the risk of stress fracture (3, 4, 7, 9).

The absence of first metatarsal fracture in this study supports the strength of the inverted Z-scarf osteotomy as demonstrated by laboratory research (12, 13). The reversal of the proximal and distal arms (Figure 4) created a construct shown to be 1.6 times stronger than the traditional configuration (12, 13). Yet no clinical research has compared the inverted construct with the traditional construct modified to increase the surface area across the dorsal shelf. Because no direct comparison was made between osteotomy designs in this study, it is not possible to attribute the absence of metatarsal fracture in this series to the inverted construct alone. Future clinical investigations could compare the inverted Z-scarf osteotomy with its more traditional modified design for hallux valgus correction in the same patient population.

Because the Z-scarf osteotomy may be more technically challenging than many procedures for hallux valgus correction, steps to minimize surgeon error may be warranted. Angling the proximal arm 120° to the longitudinal osteotomy (Figure 1) does not compromise the inherent stability of the construct, adds more dorsal surface area for screw placement, and allows easier rotation of the capital fragment by reducing the binding that may occur at the proximal cut (13). Furthermore, the inverted design is technically easier to perform because less dissection is required to fashion the dorsal proximal arm, compared with the more traditional design, which may require more of a "blind cut" for the plantar arm.

Outcomes in this study were measured in part by the major complication rate, observed in 2 (2.7%) of 73 feet. This compares

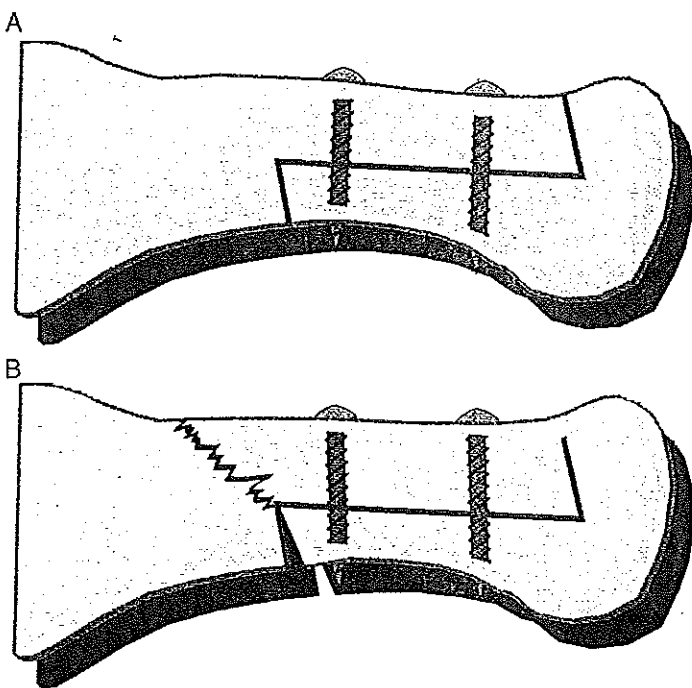


Fig. 3. Failure pattern in the traditional Z-scarf osteotomy design. (A) The traditional Z-scarf osteotomy. (B) Stress riser/fracture propagate dorsally across metatarsal shelf from the proximal plantar osteotomy with weight-bearing forces.

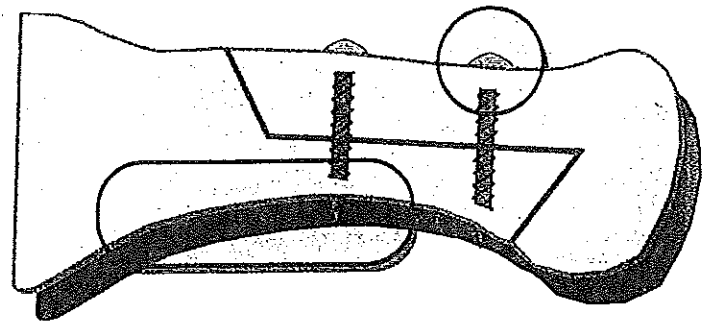


Fig. 4. The inverted Z-scarf osteotomy construct reverses the configuration of the proximal and distal arms. The construct is strengthened by the interlocking distal segment and point of screw fixation, with weight-bearing forces borne by the intact proximal plantar segment.

favorably with the average 8% major complication rate observed in the literature for the traditional Z-scarf osteotomy and its variations. In this study, the single case of distal screw pull-out and resultant mild malunion with first metatarsal elevation was considered a major complication because the inverted Z-scarf construct was thought to be inherently stable and stronger than the traditional design. This result was surprising given the stability afforded by the interlocking distal plantar osteotomy and corresponding point of screw fixation, but the patient's bone may have been more osteopenic than suggested by the radiographs. This result underscores the importance of careful patient selection for this operation.

Aside from the limitations inherent to a retrospective descriptive study design, there were several other shortcomings of this study. Objective clinical findings were not evaluated in the study population. Instead, the authors relied on patient responses to the modified University of Maryland 100-Point Painful Foot Center Scoring System (17, 33) as the measure by which to define clinical results. This scoring system has been used in several other studies for patient evaluation of hallux valgus correction (17, 29, 37, 38). Despite modifications designed to better characterize outcomes of hallux valgus surgery, this survey provides only rudimentary information about certain clinical factors such as gait, first metatarsophalangeal joint motion, and deformity recurrence as perceived by the patient (Table 1), and it cannot take the place of a foot-related quality of life outcome instrument that has previously been shown to provide valid information. It cannot take the place of standardized objective measurements. Outcomes that could not be determined include the quality and degree of first metatarsophalangeal joint motion, hallux position, hallux purchase power, first ray motion, pain within the second metatarsophalangeal joint with or without pain or a skin lesion beneath second metatarsal head, effects on the medial longitudinal arch and hindfoot position, and the quality of gait.

Despite the absence of a clinical evaluation in this study, assessment of intermediate-term clinical outcome based on patient satisfaction scores has merit. A multicenter prospective study assessing patients' perception of hallux valgus surgery outcomes demonstrated significant improvement in pain, function, and overall satisfaction as determined by 2 validated questionnaires, confirming what physicians have perceived (39). Interestingly, several outcome studies of the traditional Z-scarf osteotomy could not demonstrate a correlation between clinical or radiographic results and patient satisfaction (17, 18, 24). In fact, unfavorable clinical measurements were sometimes correlated with high patient satisfaction (17). Despite the surgeon's reliance on clinical and radiographic parameters as a measure of successful outcome in hallux valgus surgery, the importance of the patient's perception about the final result should not be overlooked. Indeed, Schoen et al (17) remark on the multifactorial nature of a good result and caution

against the attention that may be given to established measurements in the face of a satisfied patient. Unfortunately, in our study patients did not complete the questionnaire before surgery, so no baseline comparison with postoperative outcomes was available. This was a limitation of the retrospective design.

Analysis of results was limited to descriptive data; statistical associations could not be derived. In addition, patient survey results were not correlated with radiographic measurement outcomes, which could have strengthened the measure of outcome in this study. Although a high patient survey response rate in this study (90%) minimizes the potential bias of patients with primarily or exclusively favorable results completing the survey, it is possible the remaining 6 patients who did not return the questionnaire experienced a less favorable result. Another source of potential bias, radiographic evaluation, was eliminated by obtaining measurements from one author (V.N.F.) who was not involved in either the patient's surgery or clinical follow-up. Radiographic outcome was limited to an average of 14 weeks, another significant limitation of this study. The senior author (J.M.M.) does not require longer follow-up after surgery for hallux valgus deformity unless the patient is dissatisfied with his/her outcome.

The results of this study demonstrates the inverted Z-scarf osteotomy to afford predictable good to excellent intermediate-term outcomes in hallux valgus surgery based on high patient satisfaction scores. Desirable initial radiographic results and a low complication rate supports laboratory research on the improved strength of the inverted construct compared with the more traditional design. With proper patient selection and close attention to technical elements of the procedure, the inverted Z-scarf osteotomy offers the foot and ankle surgeon a reliable first metatarsal shaft procedure for the correction of hallux valgus deformity.

References

- Kelikian H. *Hallux Valgus, Allied Disorders of the Forefoot and Metatarsalgia*. pp 1–5, WB Saunders, Philadelphia, 1965.
- Meyer M. Eine neue modification der hallux valgus operation. *Zen Fur Chir* 53:3265–3268, 1926.
- Zygmunt KH, Gudas CJ, Laros GS. Z-bunionectomy with internal screw fixation. *J Am Podiatr Med Assoc* 79:322–339, 1989.
- Weil LS, Borrelli AH. Modified Scarf bunionectomy: our experience in more than 1000 cases. *J Foot Surg* 30:609, 1991.
- Weil LS. Scarf osteotomy for correction of hallux valgus: historical perspective, surgical technique, and results. *Foot Ankle Clin* 5:559–580, 2000.
- Barouk LS. Scarf osteotomy of the first metatarsal in the treatment of hallux valgus. *Foot Disease II* 1:35–48, 1991.
- Barouk LS. Scarf osteotomy for hallux valgus correction: local anatomy, surgical technique, and combination with other forefoot procedures. *Foot Ankle Clin* 5:525–528, 2000.
- Glickman S, Zahari DT. Short "Z" bunionectomy. *J Foot Surg* 25:304–306, 1986.
- Kramer J, Barry LD, Helfman DN, Mehnert JA, Pokrifcak VM. The modified Scarf bunionectomy. *J Foot Surg* 31:360–366, 1992.
- Duke HF. Rotational Scarf (Z) osteotomy bunionectomy for correction of high intermetatarsal angles. *J Am Podiatr Med Assoc* 82:352–360, 1992.
- Steck JK, Ringstrom JB. Long Z-osteotomy: a review and new modification to correct troughing. *J Foot Ankle Surg* 40:305–310, 2001.
- Chang TJ, Yu G, Ruch J. The inverted SCARF bunionectomy. In *Reconstructive Surgery of the Foot and Leg: Update '92*, pp 265–270, edited by J Ruch, N Vickers, Podiatry Institute, Tucker, GA, 1992.
- Miller JM, Stuck R, Sartori M, Patwardhan A, Cane R, Vrbos L. The inverted Z bunionectomy: quantitative analysis of the Scarf and inverted Scarf bunionectomy osteotomies in fresh cadaveric matched pair specimens. *J Foot Surg* 33:455–462, 1994.
- Gill PW. Modification of the Scarf bunionectomy. *J Am Podiatr Med Assoc* 78:187–189, 1988.
- Pollack RA, Bellacosa RA, Higgins KR, Sharp BE, McCloskey TF. Critical evaluation of the short "Z" bunionectomy. *J Foot Surg* 28:158–161, 1989.
- Schwartz N, Groves ER. Long-term follow-up of internal threaded Kirschner-wire fixation of the Scarf bunionectomy. *J Foot Surg* 26:313–316, 1987.
- Schoen NS, Zygmunt K, Gudas C. Z-bunionectomy: retrospective long-term study. *J Foot Ankle Surg* 35:312–317, 1996.
- Crevoisier X, Mouhsine E, Ortolano V, Udin B, Dutoit M. The Scarf osteotomy for the treatment of hallux valgus deformity: a review of 84 cases. *Foot Ankle Int* 22:970–976, 2001.
- Bonnel F, Canovas F, Poiree G, Dusserré F, Vergnes C. Evaluation of the Scarf osteotomy in hallux valgus related to distal metatarsal articular angle: a prospective study of 79 operated cases. *Rev Chir Orthop Reparatrice Appar Mot* 85:381–386, 1999.
- Petersen W, Seide HW. Early outcome of correction of hallux valgus with the Scarf osteotomy. *Z Orthop Ihre Grenzgeb* 138:258–264, 2000.
- Kristen KH, Berger C, Stelzig S, Thalhammer E, Posch M, Engel A. The SCARF osteotomy for the correction of hallux valgus deformities. *Foot Ankle Int* 23:221–229, 2002.
- Coetzee JC. Scarf osteotomy for hallux valgus repair: the dark side. *Foot Ankle Int* 24:29–33, 2003.
- Freslon M, Gayet LE, Bouche G, Hamcha H, Nebout J, Pries P. Scarf osteotomy for the treatment of hallux valgus: a review of 123 cases with 4.8 years follow-up. *Rev Chir Orthop Reparatrice Appar Mot* 91:257–266, 2005.
- Jones S, Al Hussainy HA, Ali F, Betts RP, Flowers MJ. Scarf osteotomy for hallux valgus: a prospective clinical and pedobarographic study. *J Bone Joint Surg (Br)* 86-B:830–836, 2004.
- Skoták M, Behounek J. Scarf osteotomy for the treatment of forefoot deformity. *Acta Chir Orthop Traumatol Cech* 73:18–22, 2006.
- Lorei TJ, Kinast C, Klärner H, Rosenbaum D. Pedographic, clinical, and functional outcome after scarf osteotomy. *Clin Orthop Rel Res* 451:161–166, 2006.
- Aminian A, Kelikian A, Moen T. Scarf osteotomy for hallux valgus deformity: an intermediate followup of clinical and radiographic outcomes. *Foot Ankle Int* 27:883–886, 2006.
- Hammel E, Abi Chala ML, Wager T. Complications of first ray osteotomies: a consecutive series of 475 feet with first metatarsal Scarf osteotomy and first phalanx osteotomy. *Rev Chir Orthop Reparatrice Appar Mot* 93:710–719, 2007.
- Berg RP, Olsthoorn PG, Pöhl RG. Scarf osteotomy in hallux valgus: a review of 72 cases. *Acta Orthop Belg* 73:219–223, 2007.
- Deenik AR, Pilot P, Brandt SE, van Mameren H, Geesink RG, Draijer WF. Scarf versus chevron osteotomy in hallux valgus: a randomized controlled trial in 96 patients. *Foot Ankle Int* 28:537–541, 2007.
- Galli M, Muratori F, Visci F, Pezzillo F, Aulisa AG. Middle term results of I metatarsal "Scarf" osteotomy. *Clin Ter* 158:209–212, 2007.
- Chang T. SCARF procedure. In *Textbook of Bunion Surgery*, ed 3, pp 183–195, edited by J Gerbert, WB Saunders, Philadelphia, 2001.
- Myerson MS, Fisher RT, Burgess AR, Kenzora JE. Fracture dislocations of the tarsometatarsal joints: end results correlated with pathology and treatment. *Foot Ankle* 6:225–242, 1986.
- Kelikian AS. The surgical treatment of hallux valgus using the modified Z-osteotomy. *Clin Sports Med* 7:61–74, 1988.
- Buchner M, Schulze A, Zeifang F, Sabo D. Pressure distribution after scarf osteotomy for hallux valgus surgery. *Z Orthop Ihre Grenzgeb* 143:233–239, 2005.
- Smith AM, Alwan T, Davies MS. Perioperative complications of the Scarf osteotomy. *Foot Ankle Int* 24:222–227, 2003.
- Sammarco CJ, Brainard BJ, Sammarco VJ. Bunion correction using proximal chevron osteotomy. *Foot Ankle* 14:8–14, 1993.
- Blum JL. The modified Mitchel osteotomy-bunionectomy: indications and technical considerations. *Foot Ankle Int* 15:103–106, 1994.
- Thordarson DB, Rudicel SA, Ebramzadeh E, Gill LH. Outcome study of hallux valgus surgery—an AOFAS multi-center study. *Foot Ankle Int* 22:956–959, 2001.